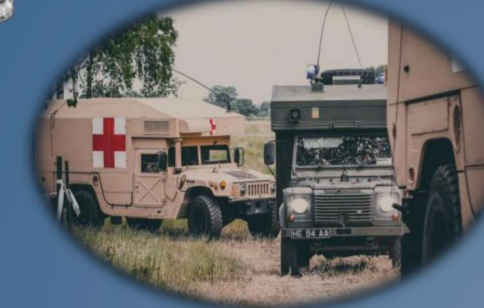
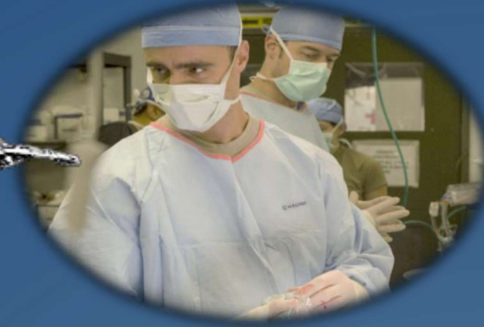
Prehospital Education and Bioengineering Innovations Panel HERETIC 2022



POI:

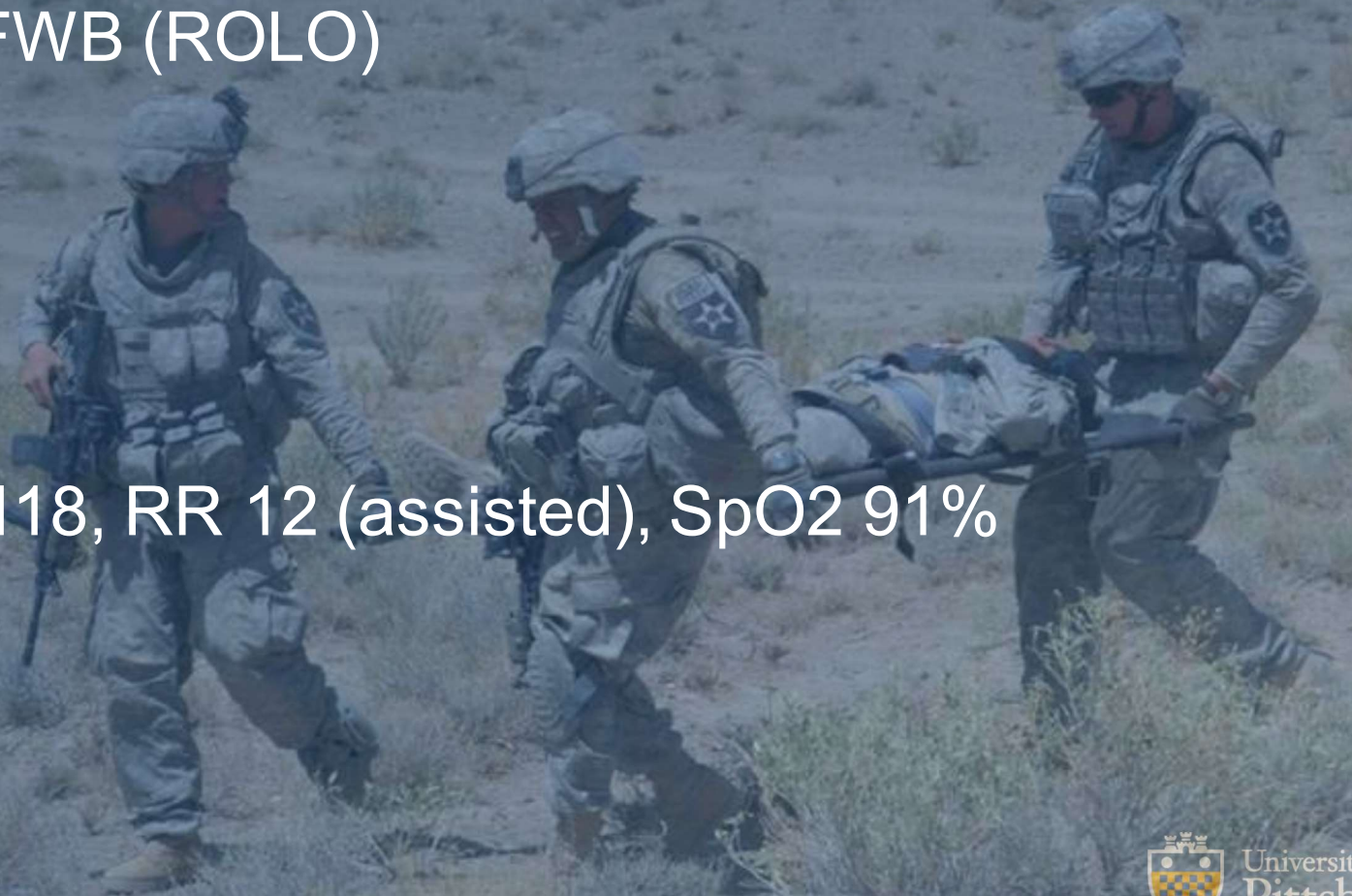- 26 y/o male in mounted vehicle IED
- Injuries to Face, Head, RLE, Abdomen
- LAC PIV placed
- BP 92/p (radial), RR 26
- No obvious source of external bleeding
- GCS 3, PERRL (4mm, sluggish)
- Nasal airway placed
- TXA 1gm, 2u CSWB

MEDEVAC:

- Sternal IO 2u FWB (ROLO)
- BVM


ROLE 2:

- BP 98/42, HR 118, RR 12 (assisted), SpO2 91%
- RSI/ETT
- + FAST



POI:

- 33 y/o male in dismounted IED
- Injuries to RUE, RLE, R Pelvis
- CAT RUE, CAT RLE, junctional TQ R inguinal, hemostatic dressing
- Sternal IO
- Manual pressure to abdomen
- TXA 1gm, Ketamine 200mg IM, Ketamine 100mg IV x3, Calcium Gluconate 1gm, Versed 2mg IV, 4u CSWB, 3u FWB (ROLO)
- BP 60/p (radial), RR 20, ETC02 25



MEDEVAC:

- Humeral IO 2u CSWB; 1u FWB (ROLO)
- Invanz 1gm IM, Ketamine 100mg IO, TXA 1gm IV
- Manual pressure was held on the pelvis and abdomen throughout treatments

ROLE 2:

- BP 64/47, HR 144, RR 8, SpO2 67%

